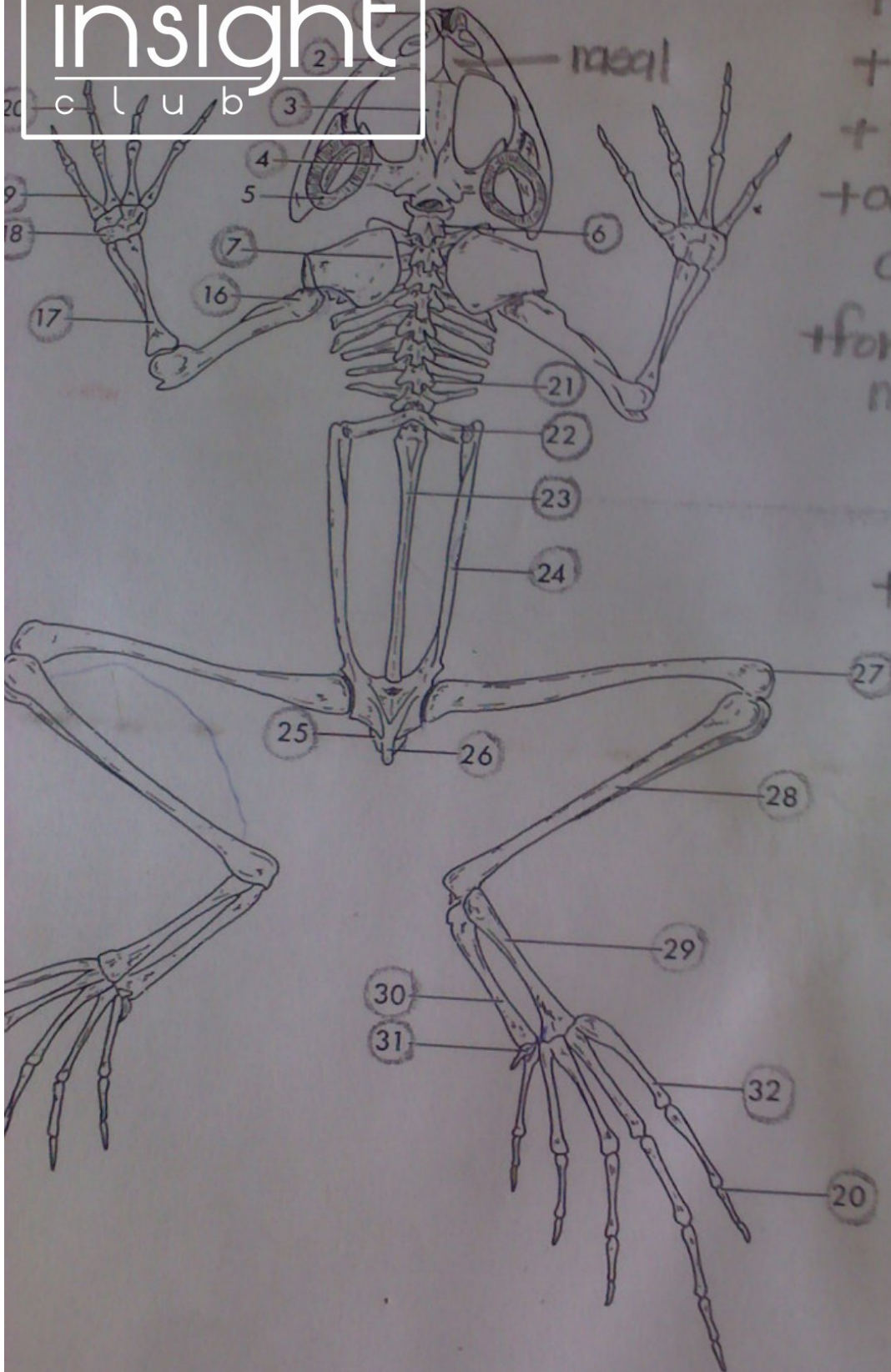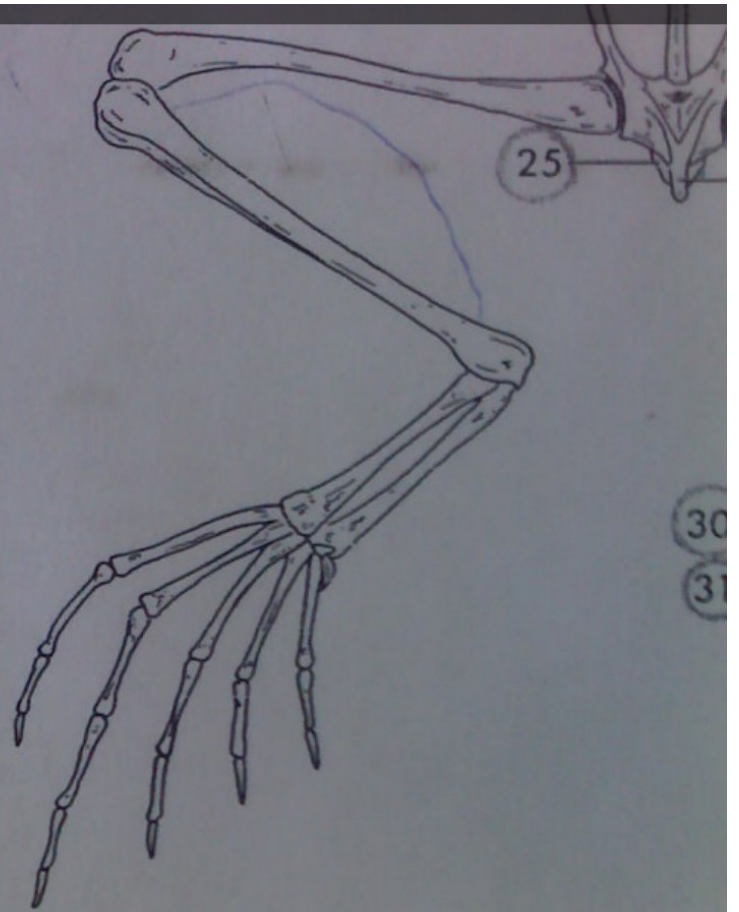
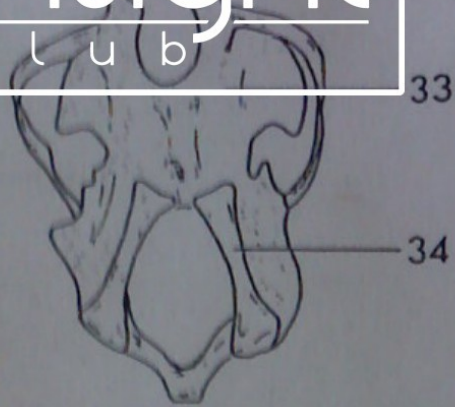
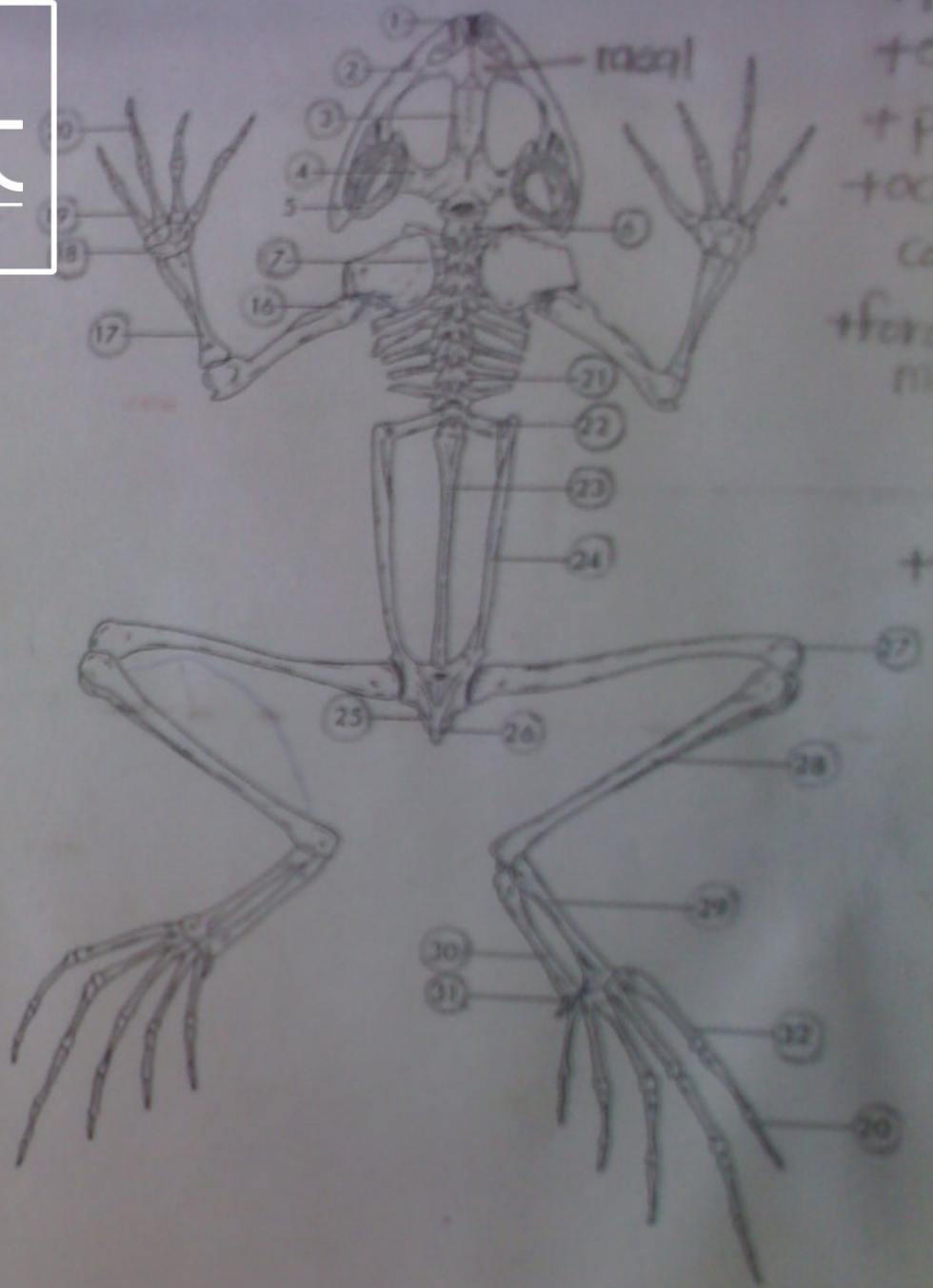
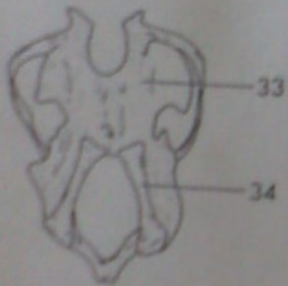
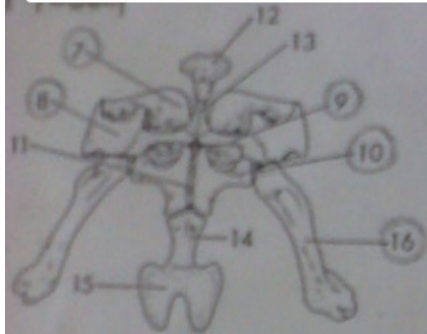


+ pterygoid
+ exoccipital
+ prootic
+ occipital
condyle
+ foramen
magnum

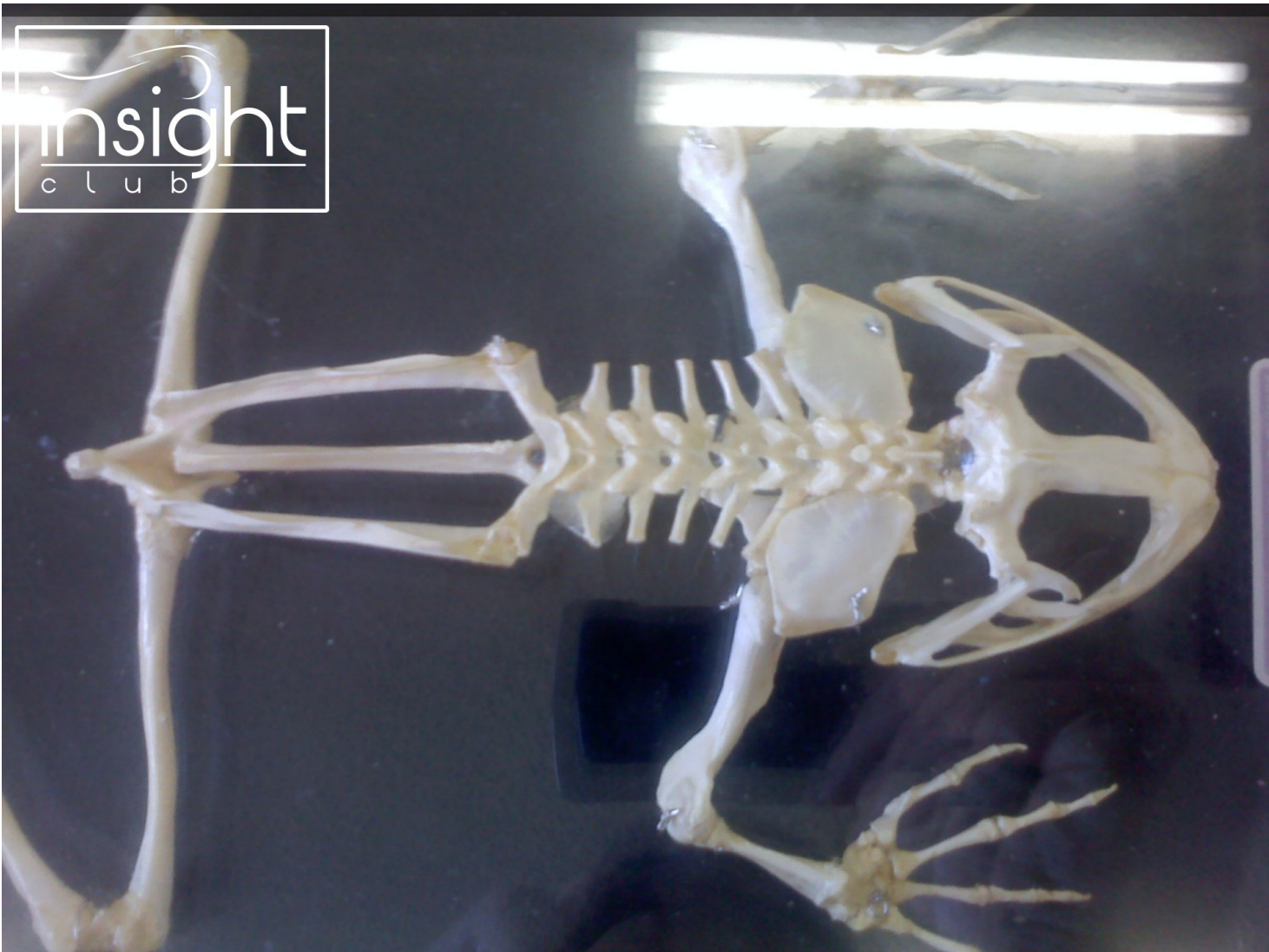
+ acetabulum



- | | | |
|-------------------------------|---------------------|-----|
| 1. Premaxilla | 12. Episternum | 24. |
| 2. Maxilla (Mandibular teeth) | 13. Omosternum | 25. |
| 3. Frontoparietal | 14. Mesosternum | 26. |
| 4. Squamosal | 15. Xiphisternum | 27. |
| 5. Tympanic ring | 16. Humerus | 28. |
| 6. Cervical vertebra (1-5) | 17. Radio-ulna | 29. |
| 7. Suprascapula | 18. Carpals | 30. |
| 8. Scapula | 19. Metacarpals | 31. |
| 9. Clavicle | 20. Phalanges | 32. |
| 10. Coracoid | 21. Vertebra | 33. |
| 11. Epicoracoid | 22. Sacral vertebra | 34. |
| | 23. Urostyle | |

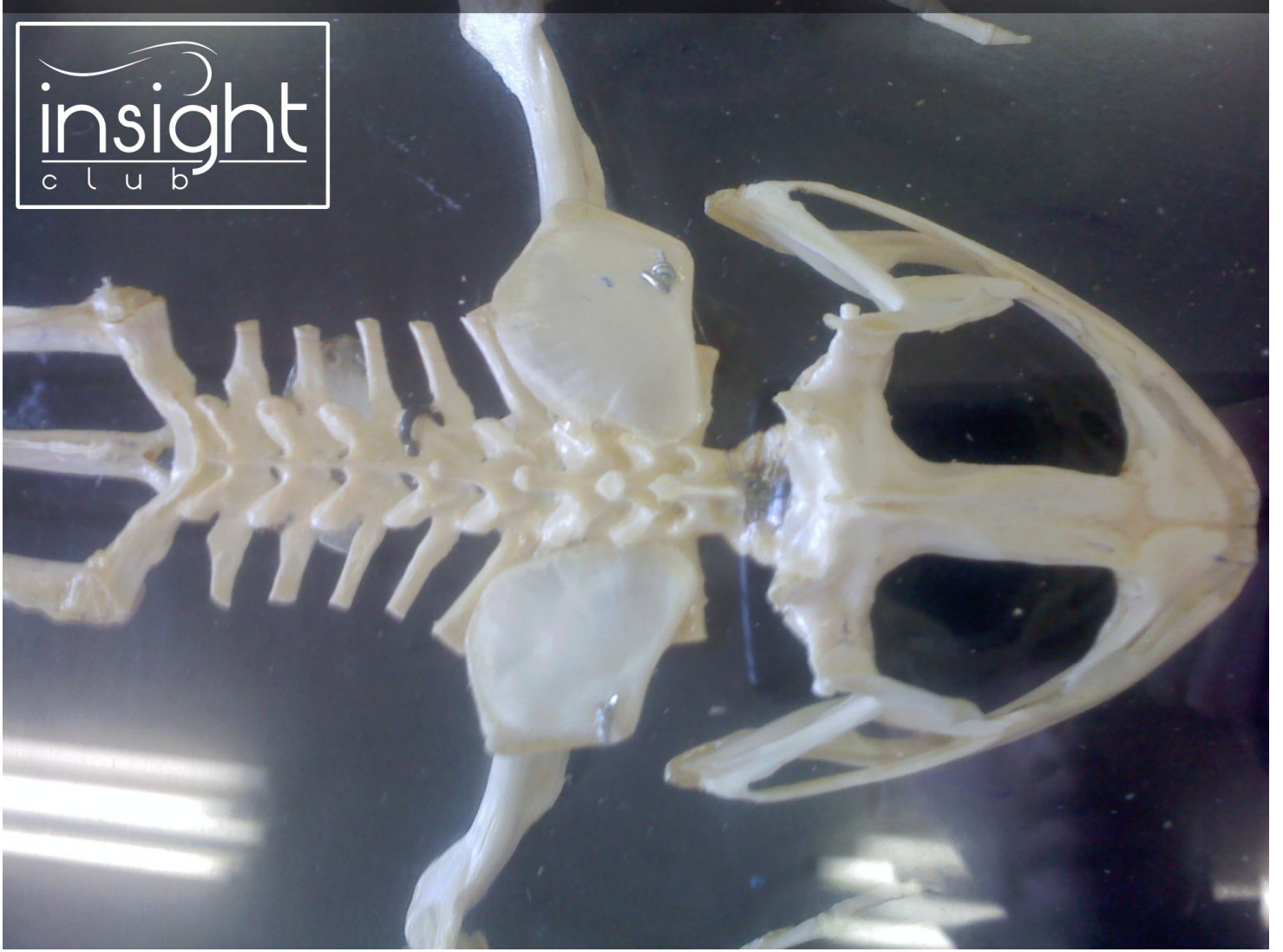

- | | | |
|----------------------|---------------------|-----------------|
| 1. Premaxilla | 12. Episternum | 23. Tibiofibula |
| 2. Maxilla | 13. Omosternum | 24. Calcaneum |
| 3. Frontoparietal | 14. Mesosternum | 25. Astragalus |
| 4. Squamal | 15. Xiphisternum | 26. Sesamoid |
| 5. Tympanic ring | 16. Humerus | 27. Metatarsals |
| 6. Cervical vertebra | 17. Radio-ulna | 28. Hyoid plate |
| 7. Suprascapula | 18. Carpal | 29. Hyoid horn |
| 8. Scapula | 19. Metacarpals | |
| 9. Clavicle | 20. Phalanges | |
| 10. Coracoid | 21. Vertebra | |
| 11. Epicoracoid | 22. Sacral vertebra | |
| | 23. Urostyle | |

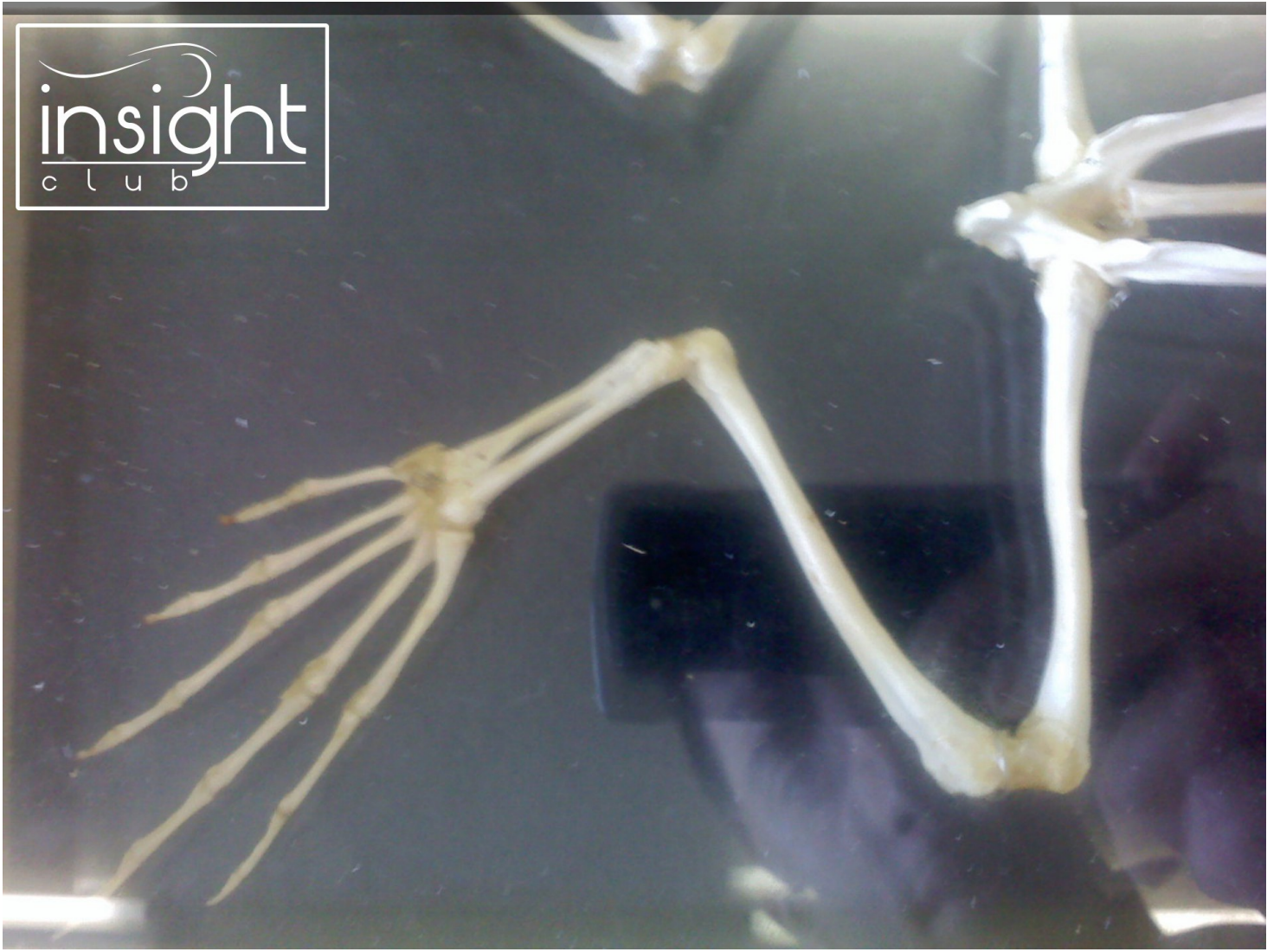


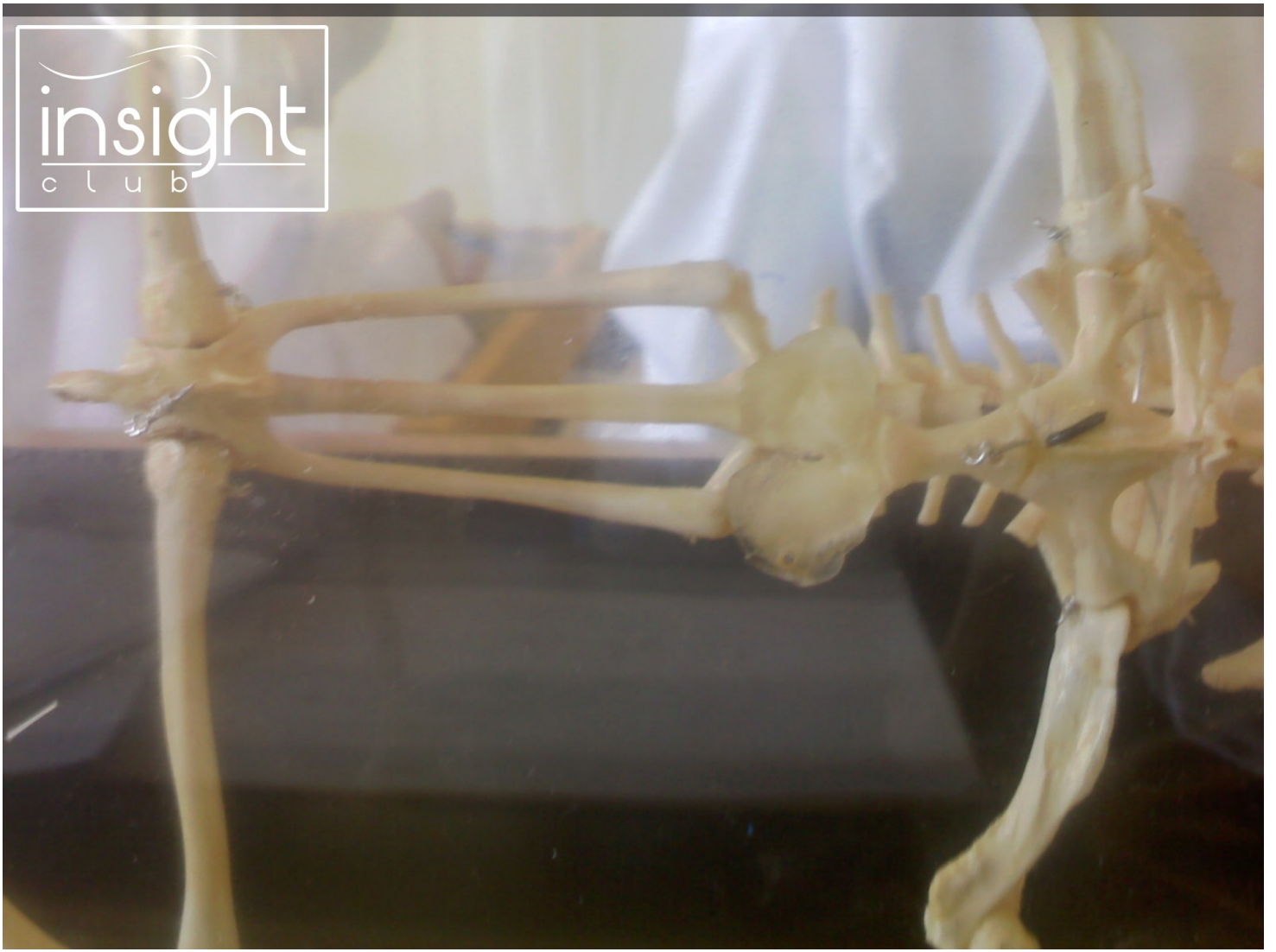insight
club

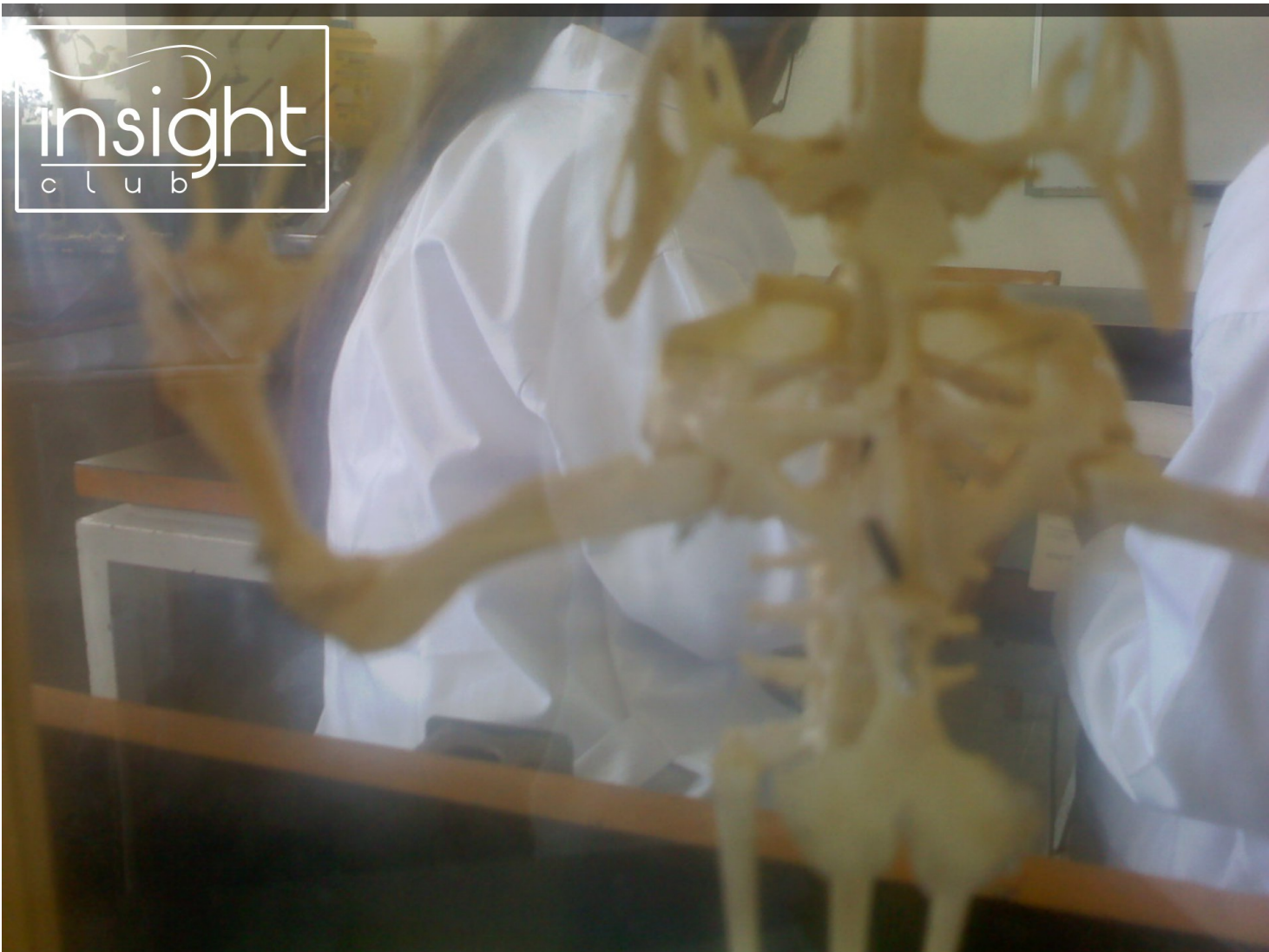insight
club

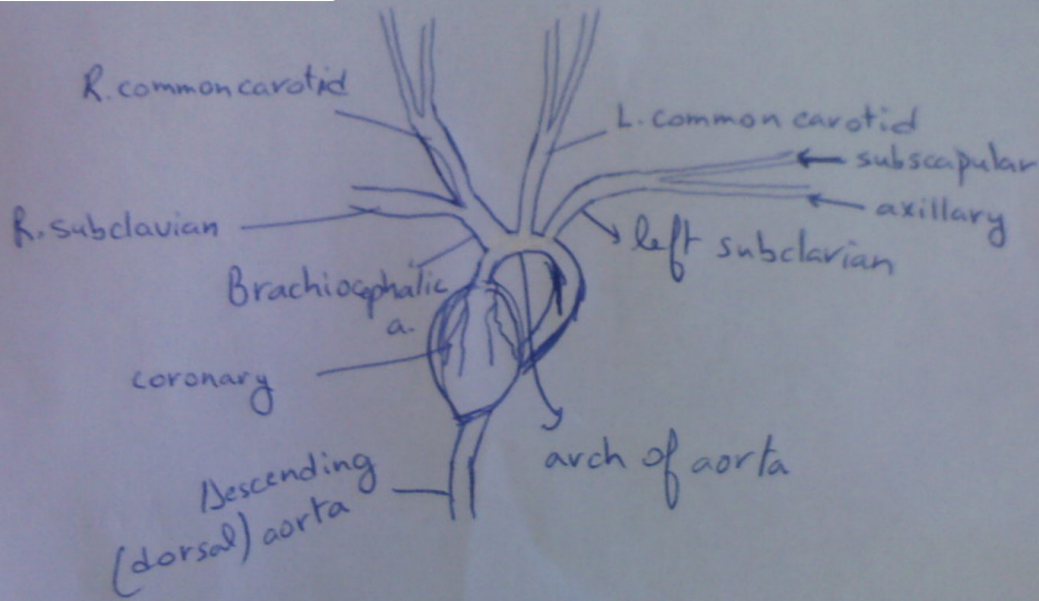


insight
club





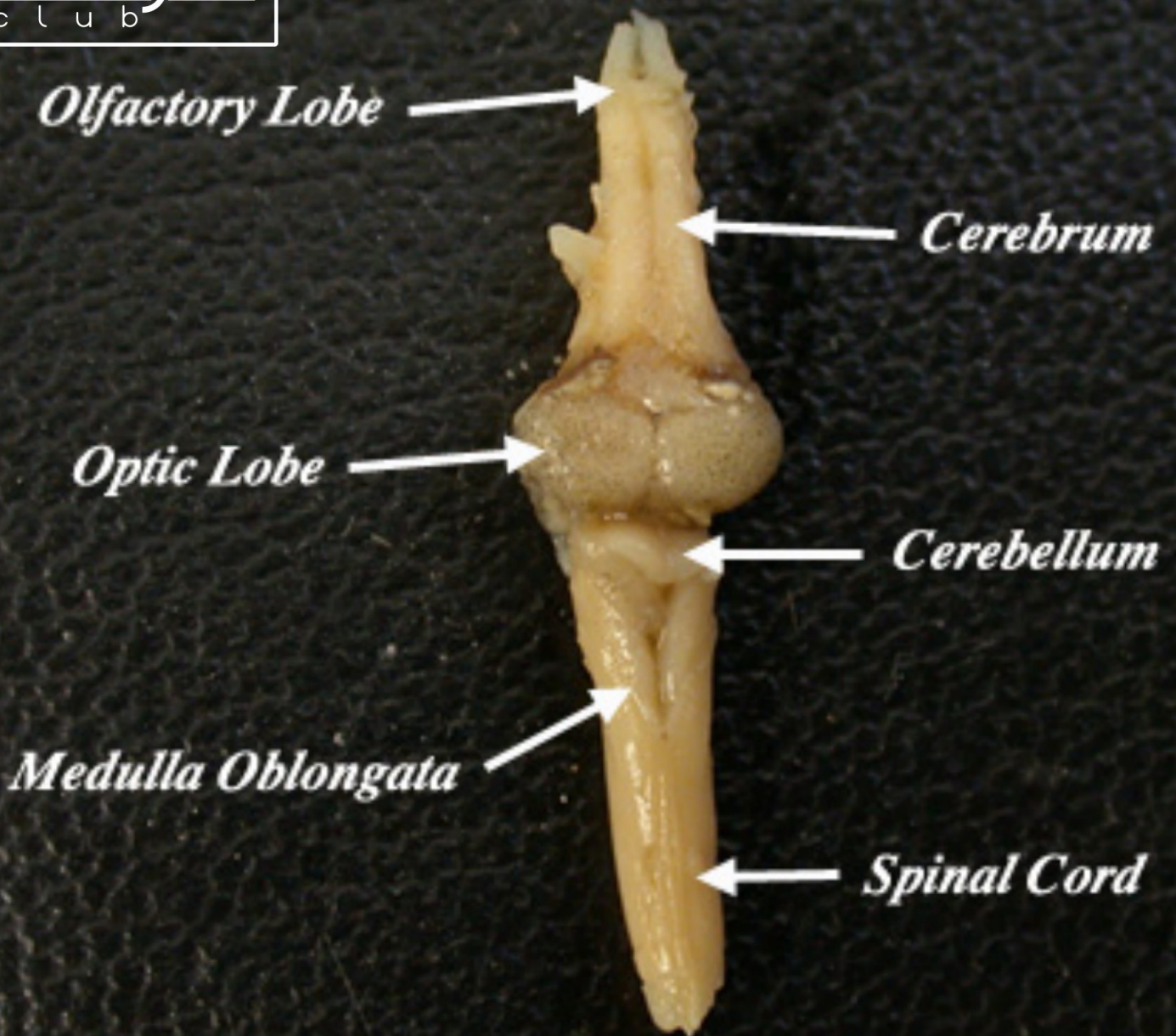


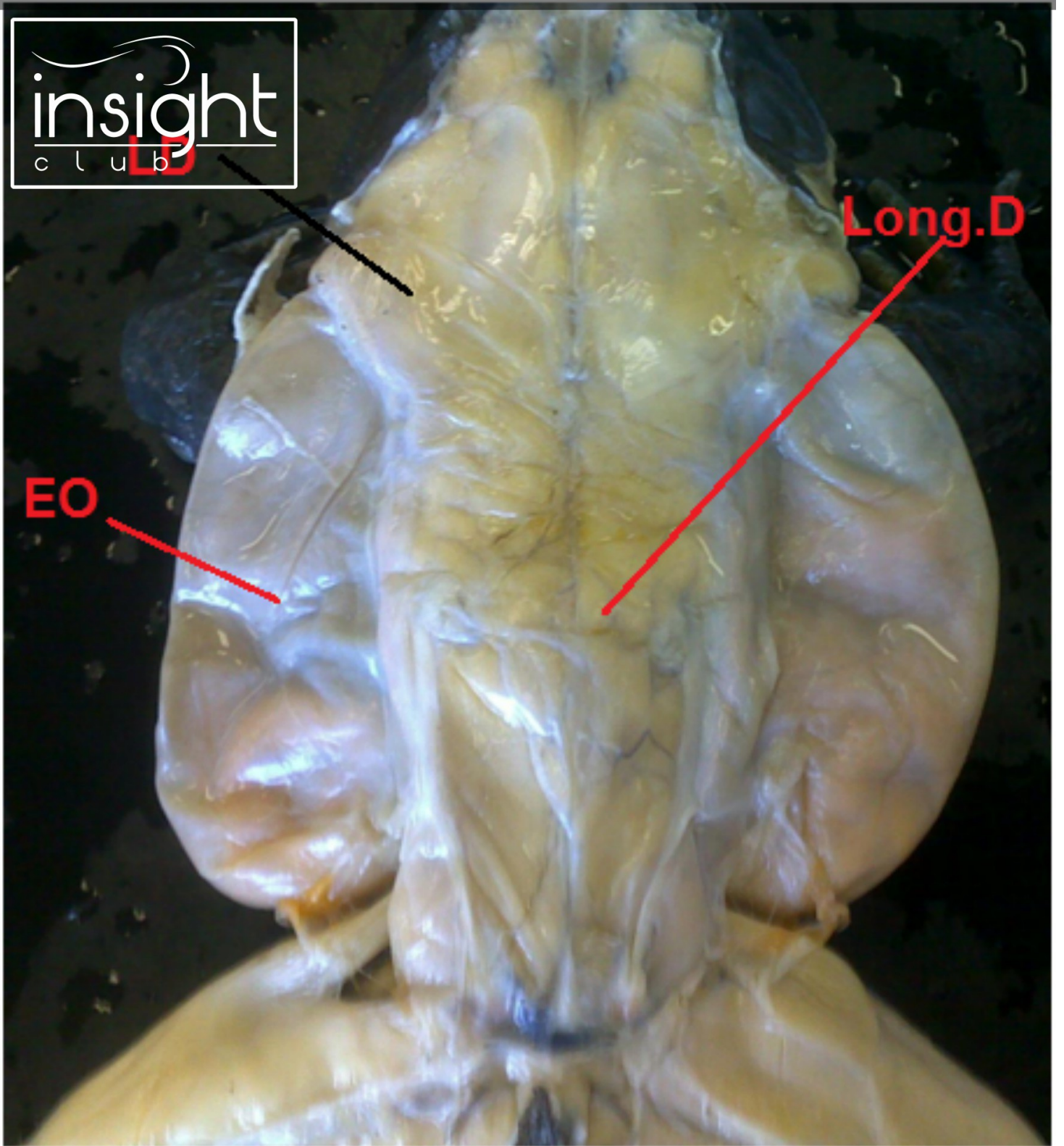


carotids: head
neck

subclavians:

Frog Brain (Dorsal View)

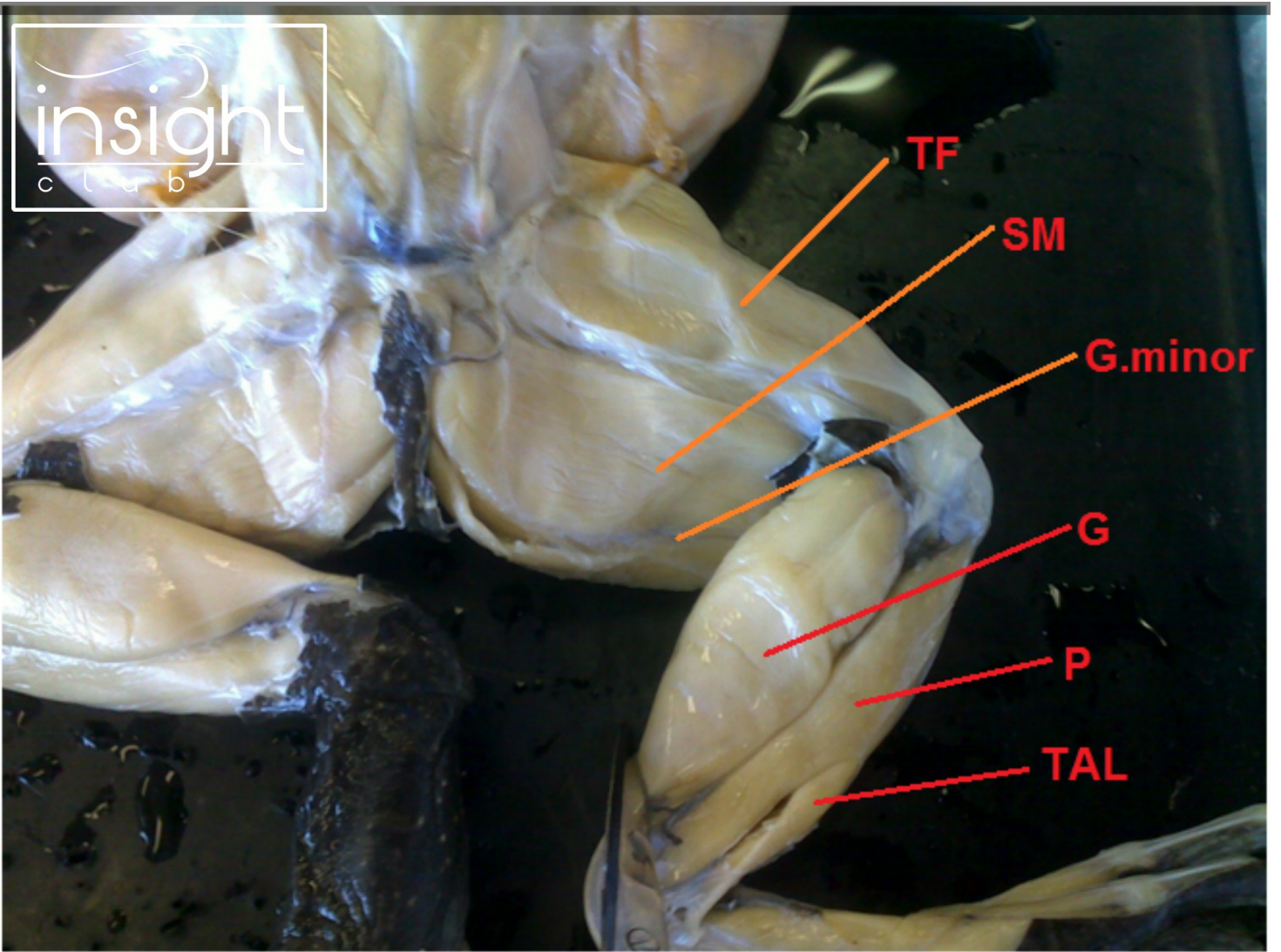


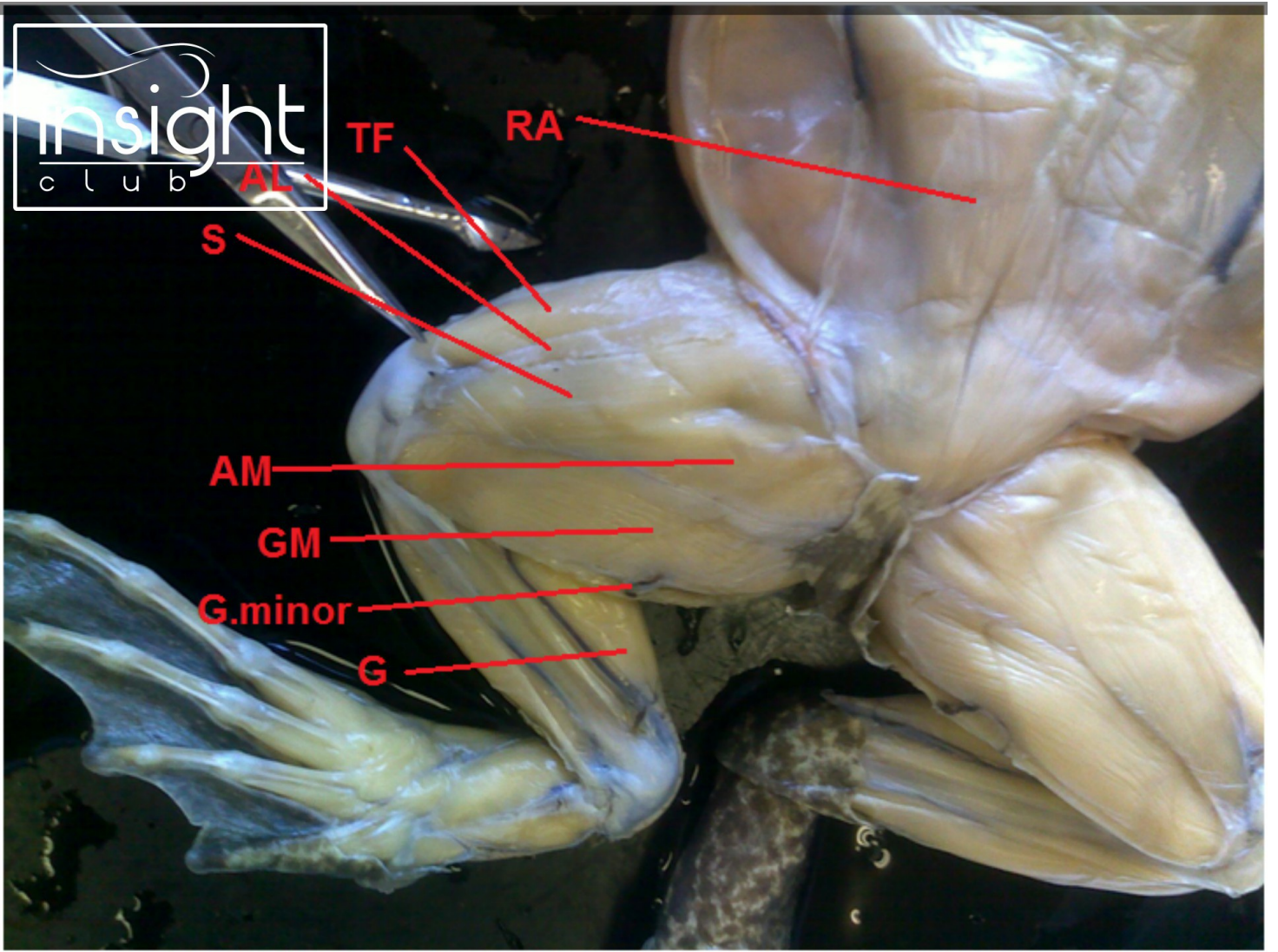


insight
club

Long.D

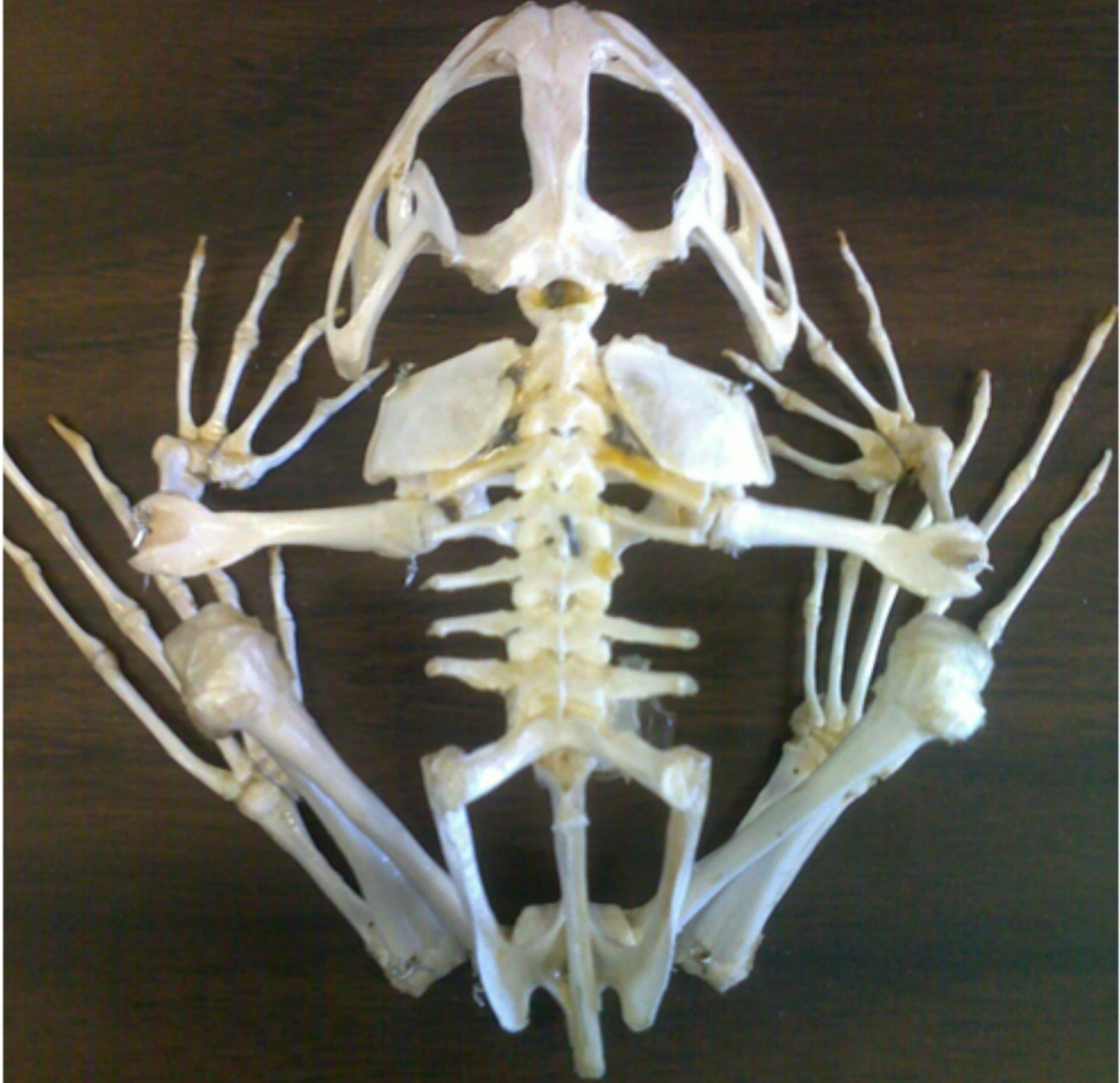EO

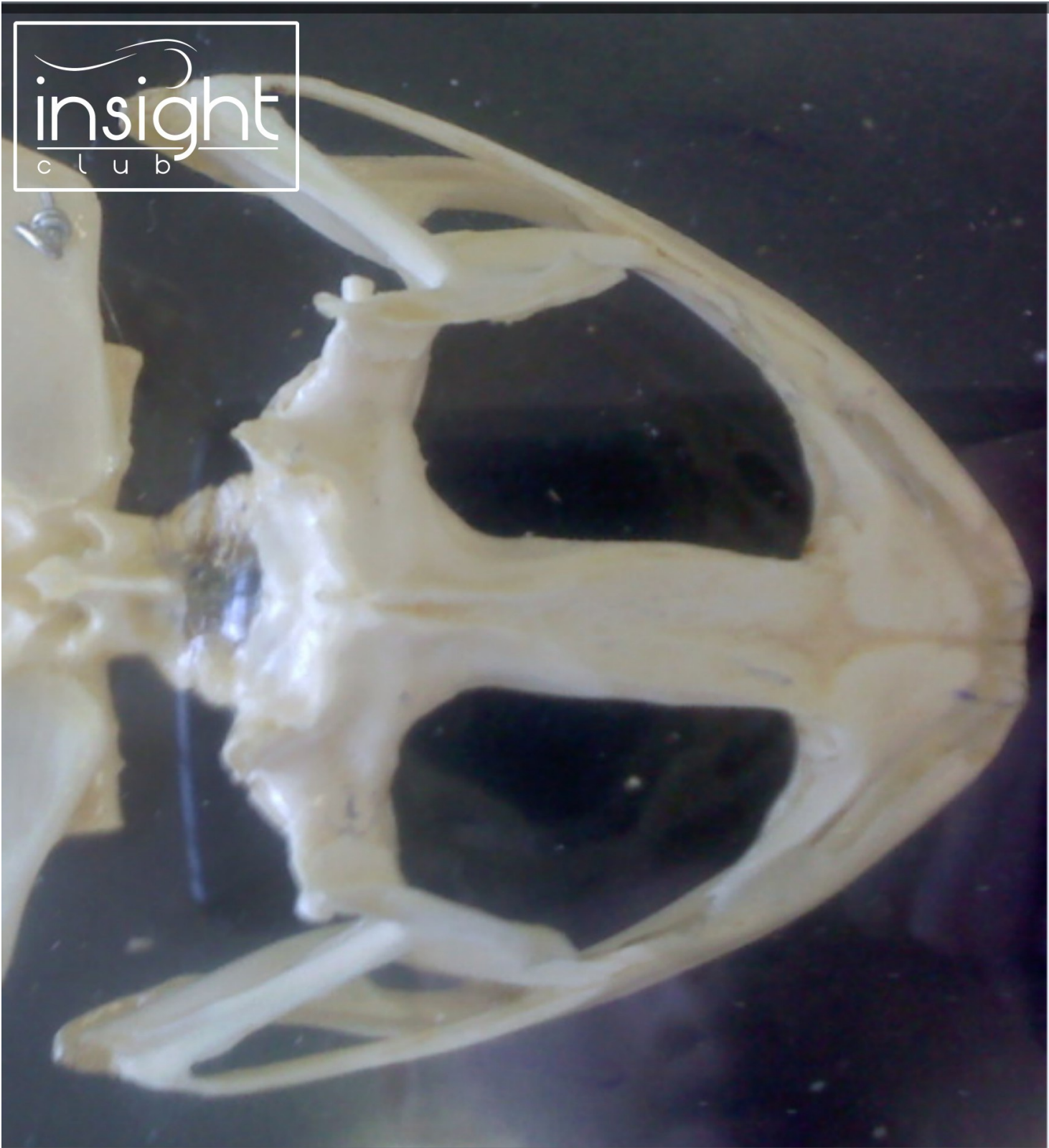



insight
club

BULLFROG SKELETON
CAROLINA BIOLOGICAL
SUPPLY COMPANY
BURLINGTON, NORTH CAROLINA 27215





insight
club